

MANAGEMENT OF SURGICAL COMPLICATION DURING CYSTIC ENUCLEATION IN MAXILLARY CENTRAL INCISOR- A CASE REPORT

Pratik Kotadia, Srinidhi Surya Raghavendra, Sania Singh

Department of Conservative and Endodontics, Sinhgad Dental College and Hospital, Pune Maharashtra, INDIA

ABSTRACT

Radicular cyst is the most common odontogenic cystic lesion of inflammatory origin. It is also known as periapical cyst, apical periodontal cyst, root end cyst, or dental cyst. It arises from epithelial residues in the periodontal ligament as a result of inflammation. The inflammation usually follows the death of dental pulp. In the management of these lesions the endodontic treatment alone is not sufficient and it should be associated with enucleation. Trauma to the adjacent anatomical structure is a common complication in the enucleation procedure. This case report describes the management of exfoliated tooth during enucleation with bone graft and splinting as an adjunct.

Received on: 24th -Feb- 2016

Revised on: 4th-April-2016

Accepted on: 8th-April-2016

Published on: 12th- June-2016

KEY WORDS

Apicoectomy; Enucleation;
Radicular Cyst

*Corresponding author: Email: srinidhi73@gmail.com Tel: +91 9372342232 Fax: + 020 24351308

INTRODUCTION

Periapical lesions are the sequelae of bacterial infection of dental pulp [1]. Many times they are asymptomatic and are diagnosed during routine dental radiographic examination; however they can have clinical presentation in the form of acute pain in a tooth [2]. These periapical lesions can be granulomas, cysts or abscesses [3, 4]. The incidence of cysts among periapical lesions varies between 6 and 55 % [5]. A radicular cyst comprises 52-68% of all cystic lesions affecting jaws [6]. Most common location is apices of involved non-vital tooth, however other times it may be present on the lateral aspect of the root. These cysts can be seen at any age and can occur in periapical area of any teeth [7]. Shear [8] reported that they have particularly high incidence in the maxillary anterior region with male predilection. Non-surgical endodontic therapy is the first line treatment for the management of these lesions [9]. Oztan and Kalaskar et al. [10, 11] have confirmed that large periapical lesions including cysts can respond favorably to nonsurgical treatment using calcium hydroxide paste. But when root canal treatment is either not possible or fails, periapical surgery can be considered as a predictable option [12]. Hyun-Kyung et al. [13] in their retrospective observational study found that the most frequent management method for the radicular cyst was enucleation with apicoectomy. The present clinical case describes the surgical management of infected radicular cyst in a 64 year old male patient using bone graft as an adjunct.

CASE DESCRIPTION

A 64 year old male reported to the Department of Conservative Dentistry and Endodontics with a chief complaint of pus discharge in the upper anterior region. On oral examination severe generalized attrition and abrasion along with sinus tract in was seen between 21 (Upper Left Maxillary Central Incisor) and 22 (Upper Left Maxillary Lateral Incisor [Figure-1a]. Sensibility testing (Electric Pulp testing) revealed loss of vitality with 21 and 22. Radiographic examination revealed large periapical lesion with 21 measuring 7×7mm in dimension [Figure- 1b].

After obtaining informed consent from the patient non-surgical endodontic treatment was initiated with placement of calcium hydroxide (Prime Dental Products, Mumbai). Medicament was placed thrice with an interval of 7 days between each, however due to inability to obtain a dry canal and also due to persistent of sinus tract, decision to undertake a surgical intervention was made. The yellowish brown aspirate was sent for cytological examination and a histological diagnosis of a radicular cyst was established.

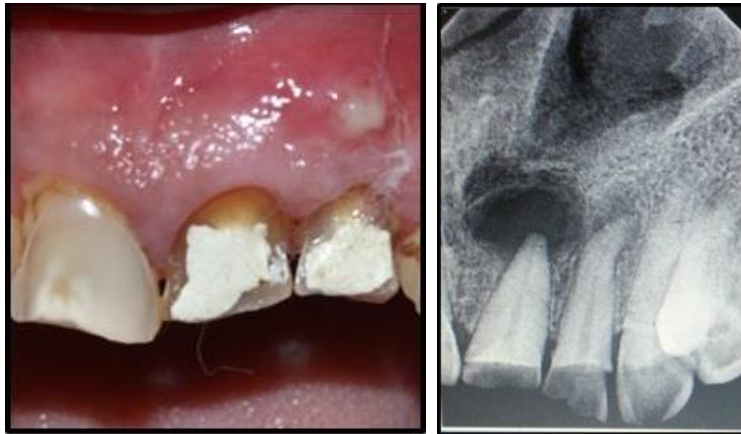

Fig: 1(a). Presence of Sinus. (b) Radiograph Showing Large Periapical Lesion

The surgical procedure was explained to the patient and the informed consent was taken. Bilateral infraorbital and nasopalatine nerve block was given with lignocaine with 1:80,000 adrenaline (BiochemPharma, Mumbai) and a full thickness mucoperiosteal flap was raised from 11 (Upper Maxillary Right Central Incisor) to 23 (Upper Maxillary Left Canine). On flap reflection the cystic lesion was evident at the apical end of 21 along with dehiscence along the length of the root [Figure- 2]. Cystic enucleation was done in toto by packing wet gauze to separate the cyst from the bone [Figure-3]. However due to absence of buccal bone support and due to tight adherence of cystic lining on the lingual aspect, enucleation led to exfoliation of 21 in the process [Figure- 4]. The exfoliated tooth was held in gauze soaked in normal saline. The apicoectomy was done with ultrasonic tips (Vista Dental Products, USA) and the cavity filled with MTA (MTA Angelus, Brasil). This was followed by its replacement in the socket. The cystic cavity was filled with Bio-Oss bone graft material (Geistlich Bio-Oss, North America [Figure- 5] and flap was closed with interrupted sutures. In order to ensure stability of 21 during healing and bone formation, splinting was done using fibre splint (Ribbond THM, Ribbond Inc., Seattle, WA, USA) which was placed on the buccal aspect from 11 to 23 for 2 weeks [Figure- 6].

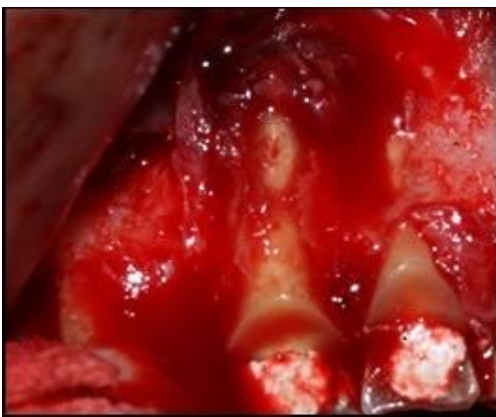

Fig: 2. Presence of dehiscence

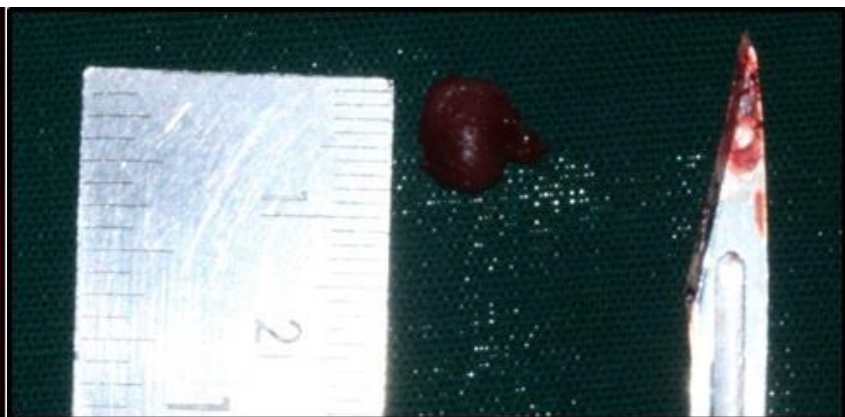


Fig: 3. In toto Cystic Enucleation with 21

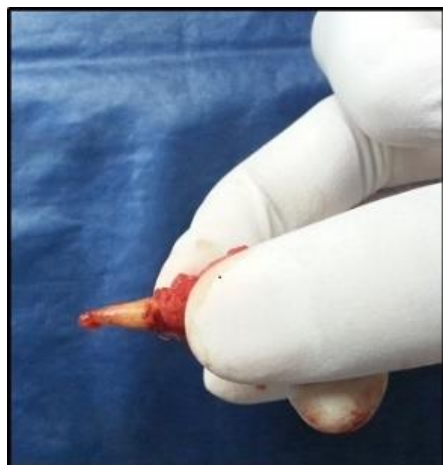

Fig: 4. Exfoliation of 21

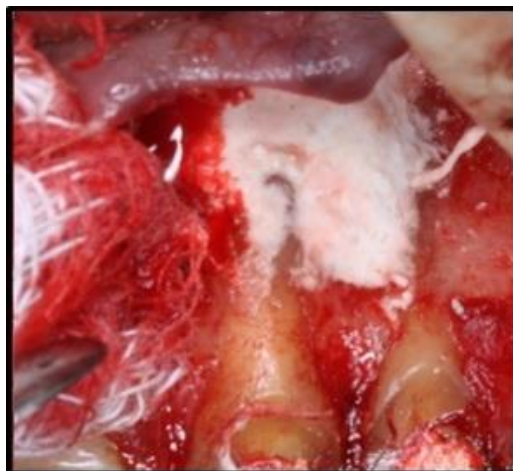

Fig: 5. Placement of Bone Graft

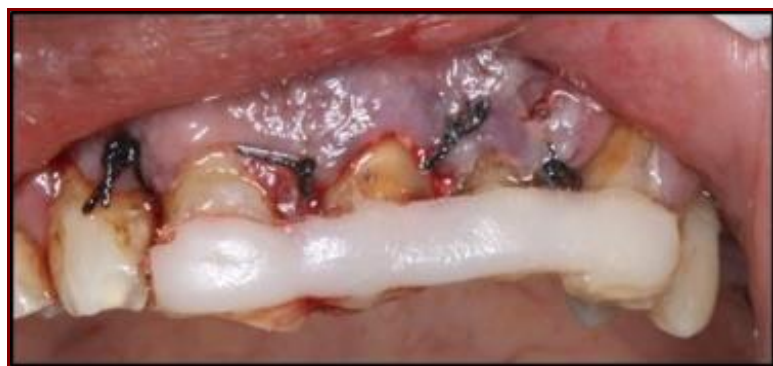

Fig: 6. Placement of Sutures and Splint

Sutures were removed after one week. Examination of 21 after removal of splint post 2 weeks revealed no presence of mobility. Follow up of the case after 6 months showed satisfactory healing of the lesion with no signs of mobility with 21 [Figure- 7].

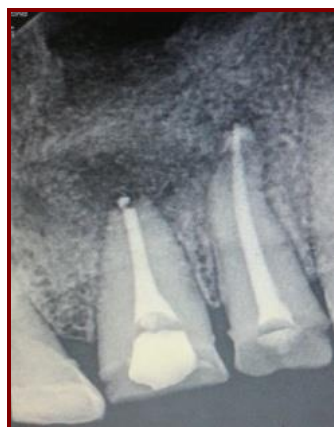

Fig: 7. Follow-Up after 6 Months

DISCUSSION

A radicular cyst is an odontogenic cyst of inflammatory origin. They are believed to be formed from epithelial cell rests of Malassez (ERM), which are remnants of Hertwig's epithelial root sheath, present within the periodontal ligament. Although the source of the epithelium is usually an ERM, other sources, such as cervical epithelium, sinus lining, or epithelium lining of fistulous tracts, have been suggested [14]. Radicular cysts are inflammatory lesions leading to bone resorption and can reach great dimensions and become symptomatic when infected or with great size due to nerve compression [15]. The choice of treatment of these lesions are determined by factors such as extension of the lesion, relation with anatomic structures, evolution, origin, clinical characteristic of the lesion, systemic conditions and cooperation of the patient. The first choice of treatment of these cysts although is a conventional endodontic procedure, however, in large lesions the endodontic treatment alone is not sufficient and it should be associated with decompression or marsupialisation or enucleation [16].

In the present case, endodontic treatment was initiated with interim calcium hydroxide dressings. The use of calcium hydroxide between sessions helps in reducing levels of bacteria better than that obtained with mechanical preparation, particularly by penetration of areas that are unreachable by instruments or irrigating solutions, such as dentinal tubules and ramifications. Calcium hydroxide has also shown clinical efficiency in reducing exudate due to its hygroscopic properties. Studies have shown that calcium hydroxide shows bactericidal activity after 2 weeks [17]. The periapical lesion, however, did not respond to the intracanal medicament as shown by the persistent sinus and weeping canal. This was probably due to the causative factor being located beyond the root canal system, viz., within the inflamed periapical tissue, thus necessitating surgical intervention.

Full mucoperiosteal flap was used as it gives maximum access and visibility of the root with reduced likelihood of healing with scar formation [18]. Often, enucleation procedures might injure adjacent anatomical structures including teeth [19]. In the present case tooth 21 exfoliated while enucleating the cyst, due to the absence of buccal bone and also due to the tight adherence of the cystic lining on the lingual aspect of the tooth. Exfoliated tooth was stored in the normal saline as it has physiological osmolality and pH [20].

Bio-Oss is a xenograft material derived from bovine bone. It undergoes a heat treatment and chemical extraction process by which the organic components are removed but maintains the natural architecture of cancellous bone. The osteoconductive property leads to effective and predictable bone regeneration. Particles of size 100×200×500Å are incorporated over time within living bone which provides long-term volume preservation. The biofunctionality of Bio-Oss is characterized by its topographic structure, hydrophilic properties and the biologic interaction that supports reliable bone formation [21].

The advantages of fibre splint are it allows physiological movement of the traumatized tooth to promote healing of the periodontal fibres and ensuring less chances of root resorption [22]. Ribbond is an ultrahigh molecular weight polyethelene fibre splint material. Woven arrangements of fibres transfers stresses efficiently throughout the fibre network, thus preventing fracture. They are highly bondable, with excellent aesthetic and are biocompatible [23]. 6 month follow up of the area showed absence of mobility with radiographic evidence of bone healing.

CONCLUSION

In the management of infected radicular cysts not responding to conventional endodontic therapy, periapical surgery can be considered as a viable option. In the present case complications during surgical procedure were managed using splinting and grafting as an adjunct.

FINANCIAL DISCLOSURE

NIL

ACKNOWLEDGEMENT

None

CONFLICT OF INTERESTS

The authors declare that they have no conflicts of interest.

REFERENCES

- [1] Möller AJ, Fabricius L, Dahlén G, Ohman AE, Heyden G. [1981] Influence on periapical tissues of indigenous oral bacteria and necrotic pulp tissue in monkeys. *Scand J Dent Res*, 89:475–484.
- [2] Barbakow FH, Cleaton-Jones PE, Friedman D. [1981] Endodontic treatment of teeth with periapical radiolucent areas in a general dental practice. *Oral Surg*, 51:552–559.
- [3] Bhaskar SN. [1966] Oral surgery--oral pathology conference No.17, Walter Reed Army Medical Center. Periapical lesions--types, incidence, and clinical features. *Oral Surg Oral Med Oral Pathol*, 21:657–671.
- [4] Lalonde ER, Leubke RG. [1986] The frequency and distribution of periapical cysts and granulomas. *Oral Surg Oral Med Oral Pathol*, 25:861–868.
- [5] Fernandes M., Ataide I de. [2010] Nonsurgical management of periapical lesions. *J Conserv Dent*, 13(4):240.
- [6] Penumatsa NV, Nallanchakrava S, Muppa R, Dandempally A, Panthula P. [2013] Conservative approach in the management of radicular cyst in a child: case report. *Case Rep Dentistry*, <http://dx.doi.org/10.1155/2013/123148>.
- [7] Nair PNR. [2003] Non-microbial etiology: periapical cysts sustain post-treatment apical periodontitis. *Endodontic Topics*, 6:96-113.
- [8] Shear M. [1992] Radicular and residual cysts. In: Cysts of the oral region, (3rd edition) *Wright Bristol*, p. 136-162.
- [9] Tolasaria S, Das UK. [2011] Surgical and nonsurgical management of bilateral periapical lesions in the maxillary anterior region. *J Surg Tech Case Rep*, 3(1):44–48.
- [10] Oztan D. [2002] Endodontic treatment of teeth associated with a large periapical lesion. *IntEndod J*, 35:73–78.
- [11] Kalaskar R, Tiku A, Damle SG. [2004] Periapical repair and apical closure of a pulpless tooth using calcium hydroxide – A case report. *J Indian Soc Ped Prev Dent*, 22:158–161.
- [12] Cohn SA. [1998] When all else fails. *AustEndod J*, 24:128–129.
- [13] Hyun-Kyung L, Kyung-Sun R, Moo-Gun K, et al. [2014] Retrospective Study of Cysts in the Oral and Maxillofacial Regions: Statistical and Clinical Analysis. *Maxillofac Plast Reconstr Surg*, 36(1):1–6.
- [14] [14] Amos MJ, Dalghous A, Alkhabuli J. [2007] Massive maxillary radicular cyst resending as facial fracture and abscess a case report. *Libyan J Med*, 211–213.
- [15] [15] Shafer WG. [2006] Cysts and Tumors of Odontogenic Origin. In: A Textbook of Oral Pathology, (5th edition), Philadelphia, WB Saunders, p.376–378.
- [16] Ribeiro Jr PD, Gonçalves ES, Neto ES, Pacenko MR. [2004] Surgical approaches of extensive periapical cyst. Considerations about surgical technique. *Salusvita*, 23:317–328.
- [17] Leonardo MR, Silveira FF, Silva LA, Tanomaru Filho M, Utrilla LS. [2002] Calcium Hydroxide Root Canal Dressing. Histopathological Evaluation of Periapical Repair at Different Time Periods. *Braz Dent J*, 13(1):17–22.
- [18] Motamedi MHK. [2015] Surgical Treatment of Odontogenic Periapical Lesions. In: A Textbook of Advanced Oral and Maxillofacial Surgery Volume 2: InTech, 209–213.
- [19] Masuda K, Kawano S, Yamaza S, et al. [2015] Complete resolution of a calcifying cystic odontogenic tumor with physiological eruption of a dislocated permanent tooth after marsupialization in a child with a mixed dentition: a case report. *World J Surg Oncol*, 13: 277.
- [20] Poi WR, Sonoda CK, Martins CM, et al. [2013] Storage media for avulsed teeth: a literature review. *Braz Dent J*, 24(5):437–445.
- [21] America G. Geistlich Biomaterials - User Benefits. Geistlich-na.com. 2016. Available at: <http://www.geistlich-na.com/en-us/professionals/bone-substitutes/bio-oss/user-benefits/>.
- [22] Mazzoleni S, Meschia G, Cortesi R, et al. [2010] In vitro comparison of the flexibility of different splint systems used in dental traumatology. *Dent Traumatology*, 26(1):30–36.
- [23] Ribbond.com. Ribbond Dental Reinforcements. 2016. Available at: <http://www.ribbon.com/Products-Dental-Reinforcements.php>.

ABOUT AUTHORS

Pratik Kotadia: Post Graduate Student, Department of Conservative Dentistry and Endodontics, Sinhgad Dental College and Hospital, Pune, Maharashtra, India

Srinidhi Surya Raghavendra: Professor and Head, Department of Conservative Dentistry and Endodontics, Sinhgad Dental College and Hospital, Pune, Maharashtra, India

Sania Singh: Post Graduate Student, Department of Conservative Dentistry and Endodontics, Sinhgad Dental College and Hospital, Pune, Maharashtra, India